

Volume: 25 ml )

Lot: \_\_\_\_\_

## Sheep Anti-Rat Glomerular Basement Membrane (GBM) Serum (PTX-001AGBM)

### *For the Induction of Passive Anti-GBM Nephritis*

#### Materials supplied:

Anti-GBM Serum, 25 ml, in 0.02 M phosphate buffered saline PBS, pH 7.3. Store at -20 C or below. Product has been heat treated at 56 °C for 30 min. Avoid repeated freeze-thaw. *Slight precipitate may form when thawed, centrifuge x 3,000-5,000 RPM , 30 minutes before injection..* Not validated in mice.

#### Directions for use:

Each bottle contains sufficient antibody to induce passive anti-GBM nephritis in at least 25 rats\* (175-200 gm) when used according to the instructions below. Please read carefully before starting the procedure.

**Injection of anti-GBM Serum:** Anesthetize rats and inject anti-GBM serum into a tail vein over a 15 second period. Production of disease is dose dependent, it is important that the complete dose of antibody is delivered (recommended dose of 0.4- 0.5 ml/ 100 gm body weight). Due to variability in antisera lots, source of rats, and investigator preferences, we recommend that dose-response studies be performed to establish the desired severity of disease from each lot of antisera.

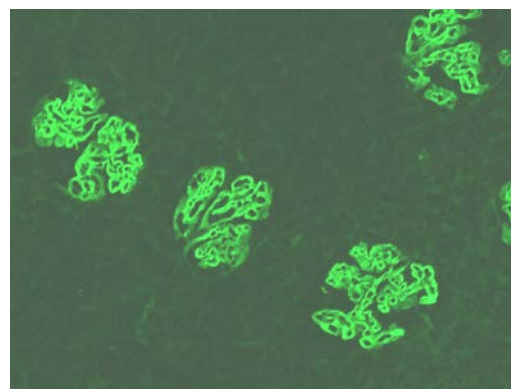
#### Description of Renal Disease:

**Heterologous disease:** Linear deposits of heterologous sheep IgG are noticeable in glomerular basement membrane by immunofluorescence within minutes increasing in intensity by 3-5 days after injection of a single bolus of anti-GBM. Rat C<sub>3</sub> also localizes in a linear pattern and proteinuria develops after 24 hours.

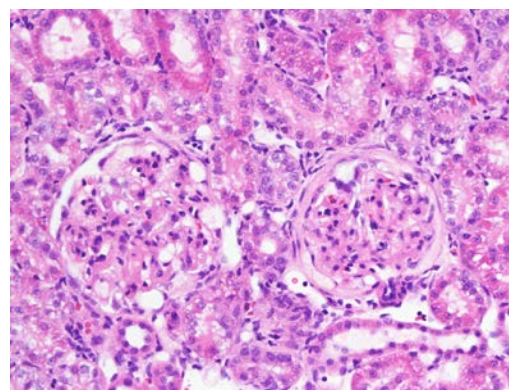
**Autologous disease** becomes noticeable after 8-10 days following administration of anti-GBM antibody evidenced by increased proteinuria and glomerular localization of rat (autologous) IgG in a linear pattern by immunohistochemistry

(Figure 1). By 3 weeks, proteinuria can be expected to reach over 200 mg/24 hours and glomerular lesions (Figure 2) are

apparent, increasing in severity over time leading to glomerulosclerosis



**Figure 1.** Immunofluorescence localization of immune deposits (rat IgG) in a linear pattern in the glomerular capillary wall 3 weeks after initiation of anti-GBM nephritis.



**Figure 2.** Glomerular crescents, mesangial hypercellularity and capillary distortion 3 weeks after initiation of anti-GBM disease.

1. Salant DJ, Cybulsky AV: Experimental glomerulonephritis. Meth. Enzymol 62:421-461, 1988.

\* Sprague-Dawley strain recommended. Other strains not tested.

# Chronic disease not verified using Probetex anti-GBM antibody.